

Rapporteurs:

Kardelen Çakıcı and Sinem Şener with
Bahar Eren Kuru and Ebru Özkan Karaca

Affiliation:

Postgraduate programme in periodontology,
Yeditepe University, Istanbul, Turkey

study

Influence of healing time on alveolar-ridge preservation

Authors:

Emilio Couso-Queiruga, Holly A. Weber, Carlos Garaicoa-Pazmino, Christopher Barwacz,
Marisa Kalleme, Pablo Galindo-Moreno, Gustavo Avila-Ortiz

Background

Alveolar-ridge atrophy is inevitably seen after tooth extraction as one of the most difficult clinical situations to overcome. Recently, prominence has been given to alveolar-ridge preservation (ARP) for the modelling of the post-extraction socket.

To restrict alveolar-ridge atrophy in the extraction socket, the surgical use of deproteinized bovine bone mineral with collagen (DBBM-C) has become a promising procedure.

There are many preclinical and clinical studies in the literature about the use of DBBM-C and collagen matrix (CM) for ARP therapy. However, until today, the human histologic aspect has been under-researched.

Furthermore, there is lack of information about the outcomes of the procedure at different post-operative time intervals.

Aim

The histomorphometric evaluation of the bone-core biopsies harvested from non-molar post-extraction sites treated with DBBM-C and CM at different healing-time points – after three, six, and nine months – as well as the evaluation of the efficacy of ARP based on clinical, digital, implant-related, and patient-reported outcomes.

Materials & methods

- This study consists of three randomised groups for different healing times: Group A, three months; Group B, six months; Group C, nine months.
- All patients had an indication for non-molar tooth extraction and were treated with the ARP approach using DBBM-C (Bio-Oss Collagen, Geistlich Pharma AG, Wolhusen, Switzerland) and CM (Mucograft Seal, Geistlich Pharma AG).
- A total of 42 patients were included and randomly divided into the three groups.
- The ARP surgical procedure, with a flapless extraction, was performed in all patients.
- Biopsies were taken from the site with a trephine drill during standard implant placement. Decisions on soft- and/or bone-tissue augmentations were made according to site's phenotypic characteristics.
- The efficacy of ARP was evaluated by obtaining histomorphometric, clinical, digital, implant-related, and patient-reported results.
- The histomorphometric results of bone-core biopsy materials were taken as the primary outcome and evaluated according to the percentages of residual xenograft within the bone as well as the mineralised and non-mineralised tissues.
- Secondary outcomes were:
 - Clinical outcomes, including the incidence and type of complications, visual dimensional assessment of wound healing, and CM exposure in millimetres.
 - Implant-related outcomes, including the assessment of the need for hard- or soft-tissue augmentation, implant insertion torque, and primary stability.
 - Digital-imaging dimensional outcomes, including: the soft-tissue changes of horizontal facial and lingual thickness, and vertical mid-facial and lingual height (mm); changes in horizontal bone width and crestal bone height (mm); and changes in alveolar-ridge contour and alveolar-bone volumes in (mm³) by using the volumetric and linear calculations.
 - Patient-reported outcome measures, including post-operative patient discomfort and overall satisfaction.

Figure 1: Sequence of treatment in a standard case that formed part of this study: (a) tooth extraction, (b) socket filled with DBBM-C, (c) socket sealed with CM after hydration, (d) CM secured with four simple interrupted sutures, (e) post-operative aspect at eight weeks, (f) full-thickness mucoperiosteal flap, (g, h) bone core biopsy sample obtained prior to implant placement. [CM, collagen matrix; DBBM-C, deproteinized bovine bone mineral with collagen].

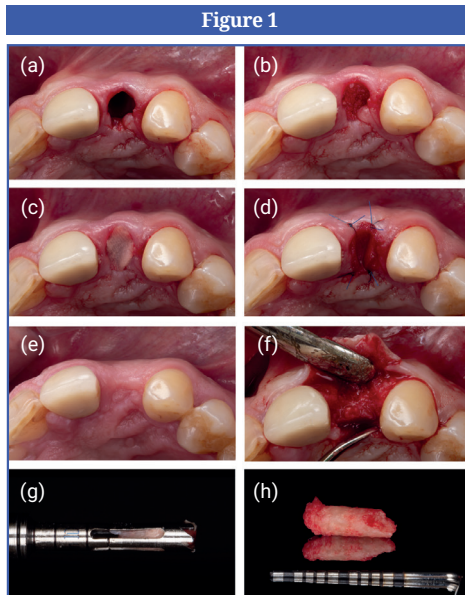
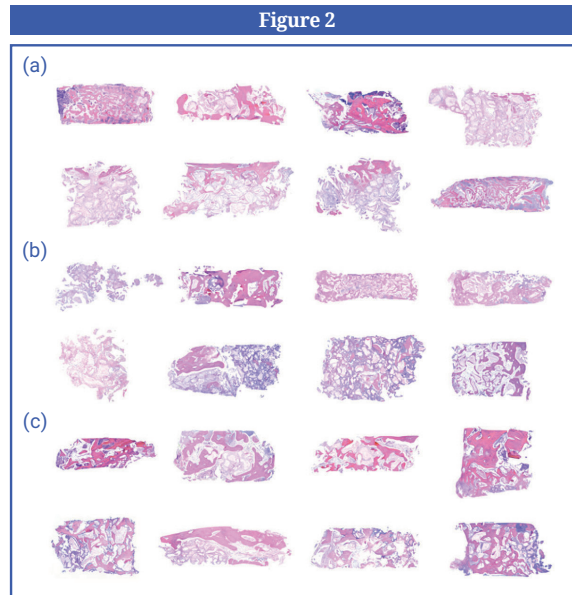


Figure 2: Photomicrographs of bone core biopsy samples (haematoxylin and eosin staining). (a) Group A, (b) Group B, and (c) Group C.



Results


- There were no significant differences in tooth-type distribution between the groups.
- Bone-core biopsies revealed a decrease in the percentages of residual xenograft particles, presenting a low degradability of the graft material, while a continuous increase in the mineralised tissue was observed over time.
- No serious adverse events or healing problems were observed. Exposure of CM was 50% in the first week and decreased to 28.2% in the second week. No CM residuals were monitored at later post-operative visits.
- Implant placement was achieved with similar insertion torque and primary stability in all sites. Bone augmentation for buccal dehiscence defects was required only at sites with a facial bone thickness of ≤ 1 mm at baseline. There was no need for soft-tissue augmentation in any of the groups.
- Regarding digital outcomes, there were no significantly different reductions in bone-width and height parameters between the groups. Overall, the findings revealed a progressive horizontal bone resorption over time and an inverse relationship between facial bone thickness and ridge-width reduction, indicating less horizontal alveolar bone resorption in the presence of thick facial bone upon extraction.
- Soft-tissue thickness was almost unaltered over time and there were no statistically significant differences between the groups in terms of facial and lingual soft-tissue height reduction.
- Volumetric analysis showed that alveolar-ridge resorption progressed over time at facial and lingual aspects, with significant differences for total and facial alveolar-ridge volumes between the groups. The overall volumetric results indicated less total and facial bone volume and alveolar-ridge contour reductions in the presence of thick facial bone upon extraction.
- At the three-month evaluations, vertical bone reduction remained unaltered, but horizontal bone loss increased over time.
- No significant differences were observed between the groups in terms of total satisfaction and postoperative discomfort of the patients.

Limitations

- Only non-molar sites were evaluated in this study. Although the selection of non-molar teeth homogenises the study, it also limits the clinical decision for posterior and mandibular anterior teeth as well as sites with extensive bone damage.
- There was no control group for comparison.
- No information was available following the implant placement regarding peri-implant health and the performance of the implant-supported prostheses.

Conclusions & impact

- Longer healing times were associated with a higher proportion of mineralised tissue within the extraction socket.
- Sites with a facial bone thickness of ≤ 1 mm upon extraction experience larger facial alveolar-ridge atrophy than sites with thicker facial bone, despite ARP.
- Sites with a facial bone thickness of ≤ 1 mm upon extraction require bone augmentation during implant placement much more frequently than sites with thicker facial bone.
- There are minimal differences in terms of clinical, dimensional, and histological outcomes from six to nine months of healing.

 JCP Digest 110 is a summary of 'Influence of healing time on the outcomes of alveolar ridge preservation using a collagenated bovine bone xenograft: A randomized clinical trial.' *J Clin Periodontol.* 2023; 50(2):132-146. DOI: 10.1111/jcpe.13744

 <https://www.onlinelibrary.wiley.com/doi/10.1111/jcpe.13744>

 Access through EFP members' page log-in: <http://efp.org/members/jcp.php>